

Rare Case of Simultaneous Diabetic Oculomotor and Trochlear Nerve Neuropathy: Case Report

by Reonal Regen

Submission date: 29-Mar-2021 09:18AM (UTC+0700)

Submission ID: 1544886590

File name: 172-1578505379.pdf (176.9K)

Word count: 2083

Character count: 11767

RARE CASE OF SIMULTANEOUS DIABETIC OCULOMOTOR AND TROCHLEAR NERVE NEUROPATHY: CASE REPORT

Lothar Matheus Manson Vanenede Silalahi^{*1}

^{*} Medical Faculty, Duta Wacana Christian University, Yogyakarta, Indonesia Siloam Hospitals Yogyakarta, Indonesia.

ABSTRACT INTRODUCTION: Diabetic cranial neuropathy is a spectrum of diabetic neuropathy. Isolated cranial nerve involvement is common as the manifestation of diabetic cranial neuropathy. The cranial nerves that frequently involved are abducens and oculomotor nerve, and trochlear nerve is the least involved. Simultaneous cranial nerve involvement is not common and needs further investigation for other possible aetiology. **CASE REPORT:** We reported a 52-year-old, diabetic and hypertensive male, presented with acute onset, first-ever, severe temporal headache with left eye ptosis, diplopia and ophthalmoplegia. Neurologic examination revealed left oculomotor and trochlear nerve palsy with sparing of pupillary function. Examination of blood D-dimer and C-reactive were normal. Head contrast MRI and MR Angiography revealed no lesion. He was diagnosed with diabetic cranial neuropathy after exclusion of other possible aetiology. **CONCLUSION:** Simultaneous involvement of two or more cranial nerve neuropathy in diabetic patient is not common and need further investigation. Exclusion of the other possible diagnosis is essential to diagnose diabetic cranial neuropathy.

KEYWORDS diabetes, neuropathy, cranial nerve

Introduction

Relationship between diabetes and neuropathy had been recognized, and the different subtypes of diabetic neuropathy existed. Many types of the nerve can be affected and one of which is cranial nerve[1]. Diabetic cranial neuropathy brings forward less interest than diabetic retinopathy so that not much literature review the clinical features that may present in diabetic cranial neuropathy[2]. Isolated cranial nerve palsy is the most common clinical presentation in diabetic cranial neuropathy, with the common cranial nerve affected is abducens and oculomotor

nerve, the least affected is trochlear nerve[1,3]. Simultaneous cranial nerve palsies in diabetic patient need further investigation to exclude the other possible aetiology before the established diagnosis of diabetic cranial neuropathy. In this article, we presented a rare case of simultaneous involvement of oculomotor and trochlear nerve involvement of diabetic cranial neuropathy.

Case report

A 52-year-old Indonesian Male, with a history of uncontrolled hypertension and diabetes mellitus, presented to the emergency department with 2-days onset of moderate-severe left temporal headache and left eye ptosis. The patient felt the progression of the ptosis and denied the diurnal pattern of ptosis. He also came with binocular diplopia, nausea and vomit occurred with his headache. That was the first headache he felt.

The patient denied any head trauma, prodromal fever, seizure, decreased of consciousness, unilateral face and body paresthesia or weakness, perioral numbness, face asymmetric, dysarthria, dysphagia and cognitive impairment.

On physical examination, he was fully conscious — his body weight 69 kg, height 169 cm, body mass index 24,5 (overweight).

Copyright © 2020 by the Bulgarian Association of Young Surgeons

DOI:10.5455/IJMRCR.merkel-cell-carcinoma

First Received: November 15, 2019

Accepted: January 06, 2020

Manuscript Associate Editor: Ivan Inkov (BG)

¹MD, Neurologist; Jl. Melati no 24A, RT 03 RW 52, Poh Ruboh, Condong Catur, Depok, Sleman Yogyakarta, Indonesia; Postal Code: 55283; Phone: +6281288173000; Email: lothar@staff.ukdw.ac.id

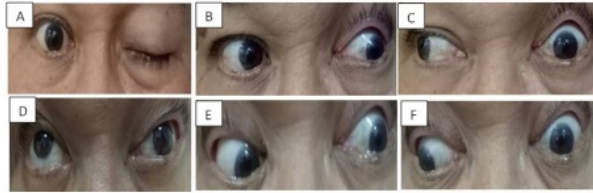


Figure 1: A. Ptosis on the left eye on normal eye position B. Normal left horizontal gaze on both eyes C. On right horizontal gaze, the left eye kept in mid-position D. On upper vertical gaze, the left eye kept in mid-position E. Normal left inferior gaze of both eyes F. On right inferior gaze, the left eye kept in mid position.

Vital sign measurement revealed hypertension and 8 points for Visual Analog Scale. On neurologic examination, he had ptosis on the left eye, impaired adduction, elevation, depression of the left eye. Movement of the right eye was normal to all directions. Both pupils were isochoric, four mm-size on both eyes, and normal direct and indirect light reflex. There was no vessel swelling and pain on palpation of the left temple. Motor and sensory examination of extremities were normal. No pathological reflex and clonus were found. The cognitive screening was normal — no sign of meningeal irritation. In conclusion, the patient had left oculomotor and abducens cranial nerve palsies with sparing of pupillary function.

There was a suspicion of subarachnoid haemorrhage with vascular aneurysm because of the acute onset of the symptoms, first-ever headache and stroke risk factor. The differential diagnosis was sinus cavernous lesion (although the trigeminal nerve, abducens nerve and pupillary reflex were normal), left temporal arteritis and cranial diabetic neuropathy. To confirm the diagnosis, the patient underwent a contrasting head MRI with MR angiography. Blood D-dimer and C-reactive protein were measured to confirm the possibility of thrombosis and arthritis. Random and fasting blood glucose, HbA1c, lipid profile and renal function were also measured.

Contrast head MRI examination revealed no lesion on sinus cavernous. Neither blood nor ischemic lesion found on brain parenchyma and subarachnoid space. On brain MR angiography, artery and vein were all normal. Neither aneurysm nor stenosis found on carotid and intracranial vessels. Quantitative measurement of D-dimer and C-reactive protein were normal. We found normal fasting blood glucose (93 mg/dL) but high result of 2-hours postprandial blood glucose (247 mg/dL) and HbA1c (10,5%). High result of HbA1c reflected the poor control of diabetes mellitus. From all the examinations, the diagnosis of diabetic cranial neuropathy was made. The patient was treated with neurotropic for the neuropathy and weak opioid combined with a non-steroid anti-inflammatory for the headache. The patient then discharged from hospital and education to control his blood glucose for the optimal treatment were given.

Discussion

We summarized the patient presented to the emergency department with painful unilateral ophthalmoplegia. Syndrome of painful ophthalmoplegia involves diverse causes and need comprehensive evaluation. The diagnosis of aneurysmal subarachnoid haemorrhage must be considered[4]. The other differential diagnosis that must be excluded were cavernous sinus thrombosis, Tolosa-Hunt Syndrome, migraine with ophthalmoplegia,

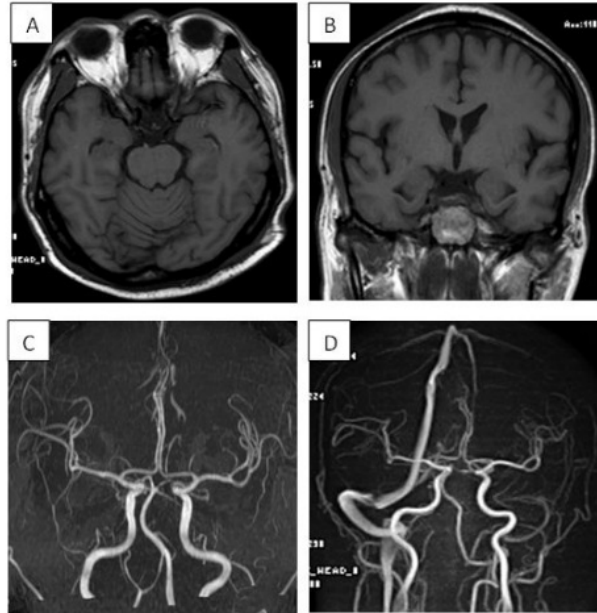


Figure 2: A and B. Axial and a coronal section of head MRI showed no lesion in the cavernous sinus. C and D. Angiography of carotid, intracranial artery and the venous system showed no aneurysm and stenosis. Note the right dominance of transverse sinus.

temporal arteritis and diabetic cranial neuropathy [5-6].

Migraine with ophthalmoplegia can be excluded because of the acute onset and did not meet the criteria for migraine[7]. MRI can be used to detect acute and subacute subarachnoid specifically the gradient echo T2[8]. Vascular aneurysm, granulomatous tissue in Tolosa-Hunt Syndrome and cavernous sinus thrombosis may be detected with MRI and MRA examination[5]. The diagnosis of diabetic cranial neuropathy will be made if the findings on head MRI, MRA, blood D-dimer and C-reactive protein were normal [4, 9-10]. The result of abnormally high HbA1c supported the diagnosis of diabetic cranial neuropathy in this patient. One study found that 70% of patient with diabetic cranial neuropathy had poorly controlled diabetes[2].

Cranial neuropathy is one of the spectra in diabetic neuropathy[10]. The common nerve affected were abducens nerve (50%), oculomotor nerve (43,3%) and trochlear nerve (6,7%)[1]. Oculomotor nerve palsy tends to be seen inpatient over the 50 years in diabetic neuropathy [11]. Isolated palsy of the nerve is a well-known manifestation of diabetic cranial neuropathy [3]. Our patient presented with combined oculomotor and trochlear nerve palsy which is very uncommon. The trochlear involvement of diabetic cranial neuropathy was uncommon and combination of oculomotor and trochlear nerve make this case more uncommon.

We found the other report that presented the patient with simultaneous oculomotor and trochlear nerve lesion. That reports found the ischemic lesion in midbrain as the aetiology of the lesion[3]. The clinical difference was the painless ophthalmoplegia while our patient presented with painful ophthalmoplegia. Meanwhile, if the ischemic lesion is still considered in our patient, the MRI result did not find any ischemic lesion in the midbrain.

The other key features of diabetic cranial neuropathy, especially with oculomotor involvement, is pupillary sparing pattern[12]. Basic mechanism of diabetic cranial neuropathy is ischemic neuronal change. The anatomical arrangement of the oculomotor nerve is periphery-located fibres nerve controlling pupillary reflex and centrally-located fibres controlling the somatic motor movement[13]. The ischemic change the nature of the disease and centrally located vasculature in the muscle are the reason behind the sparing of autonomic pupil function in diabetic oculomotor neuropathy[1].

Severe acute pain also a typical presentation of diabetic cranial neuropathy[1]. The mechanism of painful diabetic neuropathy is not fully understood. Hypothetically, chronic hyperglycemia promotes damage to the nerve and cause regeneration of nerve sprouts called neuromas. These neuromas expand, hyperexcitable and generate pain impulse[14].

Diabetic cranial neuropathy is a monophasic illness. No specific requirements are required other than prismatic help of the diplopia as the ptosis improve[11]. Diabetic cranial neuropathy regresses spontaneously after three months on average. After an acute episode, 70% of patients will cure within six months[2]. Spontaneous resolution nature of the disease makes the clinical monitoring and equilibration of diabetes is the core of management[2]. Strict glucose control from the time of diagnosis of diabetes mellitus is the essential aspect of the treatment[11].

Conclusion

Diabetic cranial neuropathy is one spectrum of diabetic neuropathy. The common clinical presentation is an acute painful severe headache with ophthalmoplegia. The key features are oculomotor nerve palsy with sparing of pupillary reflex. Simultaneous involvement of two or more cranial nerve in diabetic cranial nerve patient are uncommon and need further investigation to exclude the other diagnosis. Exclusion of the other possible diagnosis is essential to diagnose diabetic cranial neuropathy. Diabetic cranial neuropathy is a monophasic illness, recover spontaneously and need strict control of diabetes as the main management.

Conflict of interest

No conflict of interests.

References

1. Tracy J, Dyck J. The Spectrum of Diabetic Neuropathies. *Phys Med Rehabil Clin N Am* 2008;19:1.-2008;19:26
2. Lajmi H, Hmaied W, Jalel WB, Chelly Z, Yakhlef AB, Zineb FB et al. Oculomotor palsy in diabetics. *J Fr Ophtalmol* 2017;1836:1.-2017;1836:5
3. Papanas N, Heliopoulos I, Piperidou H, Maltezos, E. Simultaneous, painless, homolateral oculomotor and trochlear nerve palsies in a patient with type 2 diabetes mellitus. Neuropathy or brainstem infarction?. *Acta Diabetol* 2006;43:19.2006;43:21
4. Shiode T, Oya S, Matsui T. A Case of the Internal Carotid Artery–Posterior Communicating Artery Aneurysm Mimicking Tolosa – Hunt Syndrome. *NMC Case Report Journal* 2015;1:1.-2015;1:3
5. Hung CH, Chang KH, Chu CC, Liao MF, Chang HS, Lyu RK et al. Painful ophthalmoplegia with normal cranial imaging. *BMC Neurology* 2014;14:1.-2014;14:7
6. Quinn R, Hawkes C, Lodhi A, Tang S, Beattie KA, Adel BV et al. Ophthalmoplegia in an Elderly Woman with Giant Cell Arteritis. *Rheumatol Adv Pract* 2018;2:1.-2018;2:3
7. Weatherall, MW. The diagnosis and treatment of chronic migraine. *Ther Adv Chronic Dis* 2015;6(3):115.-2015;6(3):123
8. Mitchell P, Wilkinson ID, Hoggard N, Paley NMJ, Jellinek DA, Powell T et al. Detection of subarachnoid haemorrhage with magnetic resonance imaging. *J Neurol Neurosurg Psychiatry* 2001;70:205.-2001;70:211
9. Al-hashel JY, Ahmed SF, Youssry D, Alroughani RA, Ismail II, Vembu P. The Value of D-dimer Test for Diagnosis of Cerebral Venous Thrombosis in Emergency Medicine. *Emerg Med* 2015;5:4.-2015;5:6
10. Kermani TA, Schmidt J, Crowson CS, Ytterberg SR, Hunder GG, Matteson EL et al. Utility of Erythrocyte Sedimentation Rate and C-Reactive Protein for the Diagnosis of Giant Cell Arteritis Tanaz. *Semin Arthritis Rheum* 2013;41:866.-2013;41:871
11. Llewelyn JG. The Diabetic Neuropathies: Types, Diagnosis and Management. *J Neurol Neurosurg Psychiatry* 2003;74:15.-2003;74:19
12. Venkatesan PE, Gnanashanmugam G, Parimalam N, Pranesh MB. Diabetes plus third nerve palsy not always diabetic third nerve palsy. *J Post Grad M* 2015;61:50.-2015;61:52
13. Chou PY, Wu KH, Huang P. Ptosis as the only manifestation of diabetic superior division oculomotor nerve palsy. *Medicine* 2017;96:45.-2017;96:46
14. Aslam A, Singh J, Rajbhandari S. Pathogenesis of Painful Diabetic Neuropathy. *Pain Research and Treatment* 2014;2014:1.-2014;2014:7

Rare Case of Simultaneous Diabetic Oculomotor and Trochlear Nerve Neuropathy: Case Report

GRADEMARK REPORT

FINAL GRADE

/0

GENERAL COMMENTS

Instructor

PAGE 1

PAGE 2

PAGE 3
